

C.S.F RHINORRHOEA

MIRACLES OF HOMOEOPATHY

AUTHOR: ANURADHA KALLAKURI

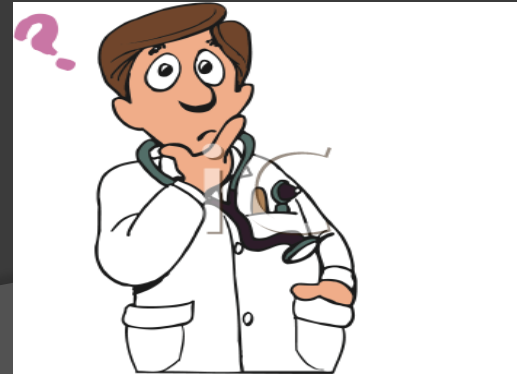
Presenting complaints

1. Severe Rhinorrhoea - left nostril, 5 months
2. Moderate headache
3. Aggravated at night
4. Sensitive to cold and heat

History of the complaints

- 10 year old girl sustained a head injury following a fall from height(12 feet).
- Lost her consciousness and was taken to an emergency hospital.
- Initial CT BRAIN showed mild concussion with no additional injuries.
- Unconscious for 72 hrs.

- Discharged on 8th day and was apparently normal.
- 3 months later, she starts having left sided rhinorrhoea, initially thought to be common cold, with multiple unsuccessful consultations.



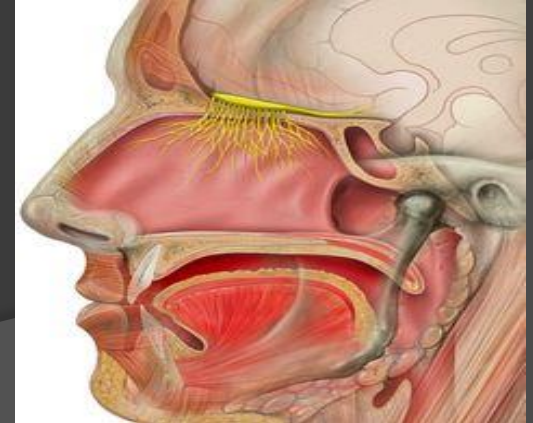
Neurosurgeon – advised CT brain

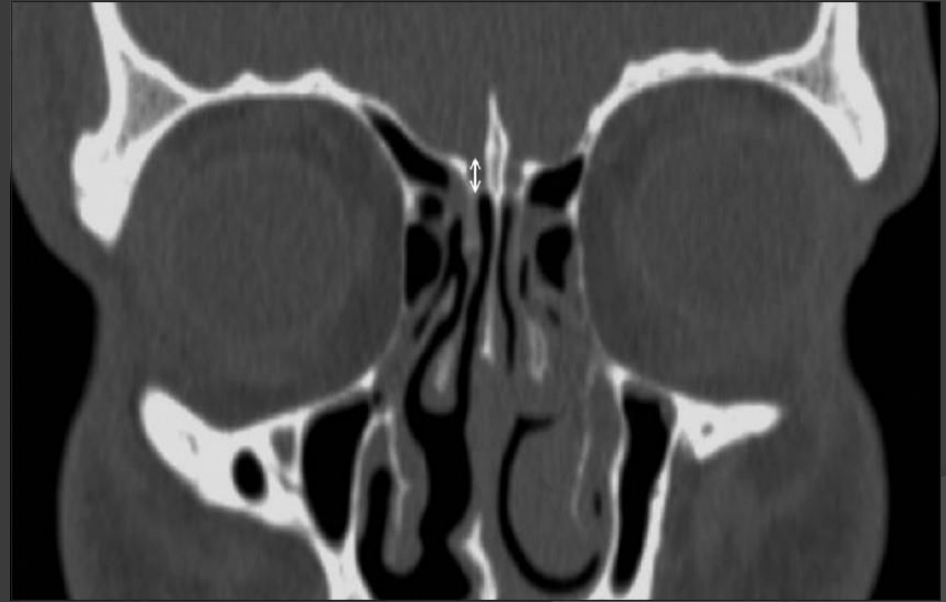
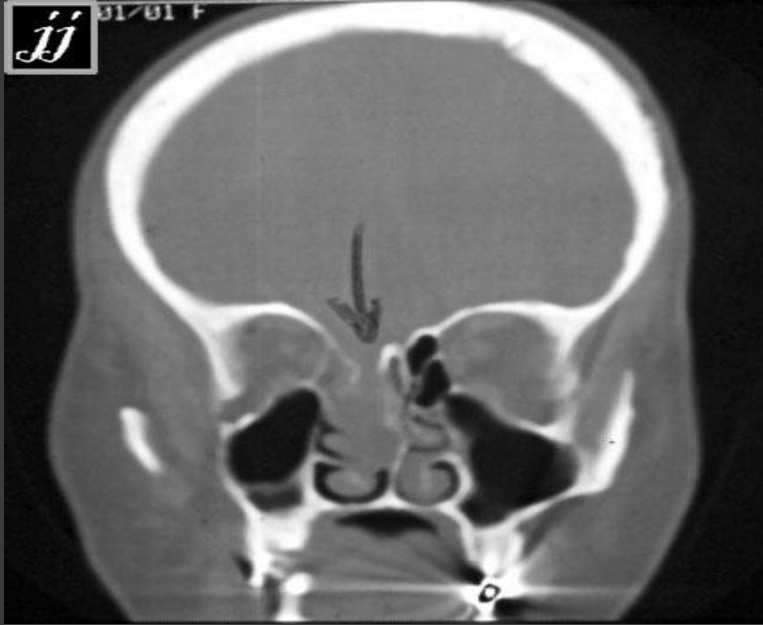

Fracture of the cribriform plate



CSF RHINORRHOEA



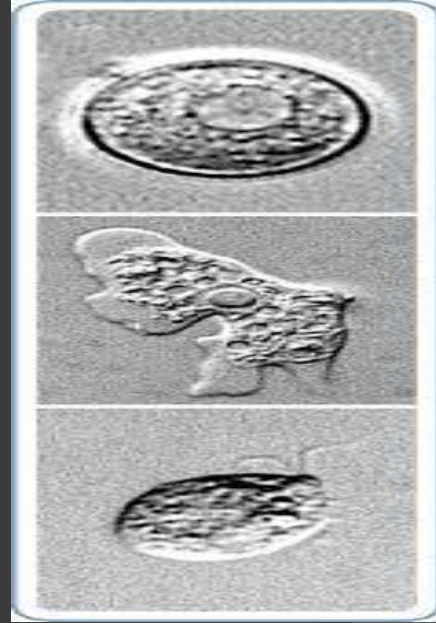
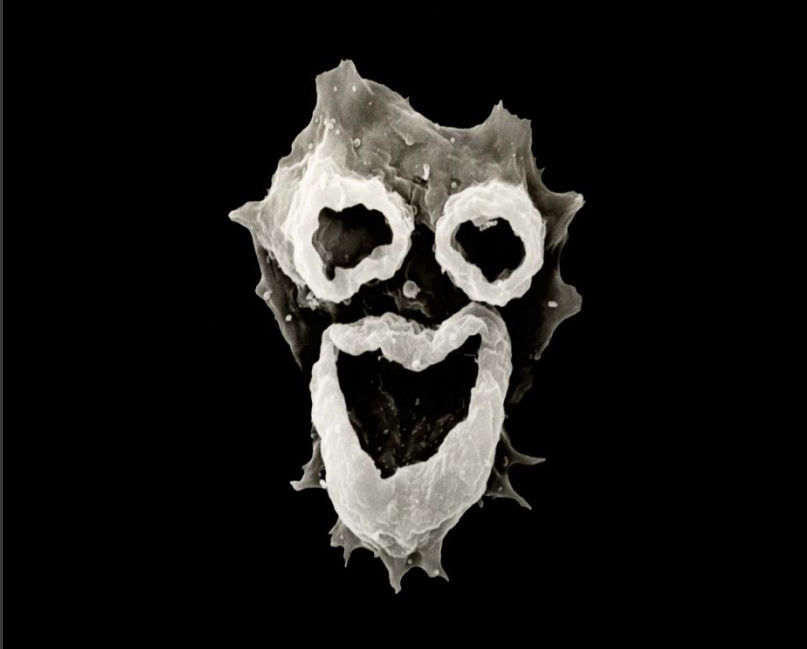

Cribriform plate

- Cribriform plate, a component of ethmoid bone is sieve like structure that separates the nasal cavity from the brain with the roof of the eye sockets situated at the sides of the plate.
- A fractured cribriform plate can result in leaking of cerebrospinal fluid in to the nose and loss of smell.

- The tiny apparatus of the plate transmitting the olfactory nerve becomes the route of ascent for a pathogen “*Naegleria fowleri*”.
- The pathogen tends to destroy Olfactory bulb and adjacent inferior surface of frontal lobe of the brain.

Naegleria fowleri



- ⦿ Bone grafting of the cribriform plate.
- ⦿ Convulsions during surgery, put on tab. phenytoin.



6 months

Recurrence of CSF Rhinorrhoea.

- ⦿ Neurosurgeon was again consulted.
- ⦿ He advised repeat surgery as there was resorption of the bone graft placed.
- ⦿ She was on treatment with antibiotics.
- ⦿ At this stage, the homeopathy physician was consulted as they were not prepared for another surgical intervention.

At this point, the treating physician was confronted with 3 challenges

- ⦿ Prevention of infection.
- ⦿ Stimulation of bone growth of cribriform plate.
- ⦿ Treating convulsions.

Leading points for 1st prescription

- Resorption(Destruction) of the bone graft suggesting syphilitic miasm.
- When the most vital organ is affected, like brain, heart, eyes, BONE and Periosteum, it is a great indication of Syphilis.
- Susceptibility to cold as well as heat.



Ph : 2469438, 2467123
RAJAHMUNDRY DIAGNOSTIC LABORATORIES PVT.LTD
-3-1, Gandhipuram-2, Near Prakash Nagar Round Park(Southside)

Patient's Name: A.SWATHI NAGAMANI.

Age: 10y Sex: Female

Ref. by : K.ANURADHA, DHMS.

Dt: 12-06-1997

CULTURE REPORT

Ref.No : 545/97

Date :12-06-1997

Nature of Material : "CSF"

Investigation :C/S

Date of Receipt : 10-06-1997

Date of Report : 12-06-1997

Culture Report : Neisseria meningococcus grown in culture.

SENSITIVE
AMIKACIN
CEFATAXIME
OFLOXACIN

RESISTANT
NORFLOXACIN
AZITHROMYCIN
SPARFLOXACIN
CEPHALEXIN
LEVOFLOXACIN
CIPROFLOXACIN
GENTAMYCIN


Signature
Dt: 12-06-1997

Suggested clinical correlation. Discuss if there is discrepancy

First prescription

- ⦿ *Mercurius solubilis*, 30c was selected.
- ⦿ After 1 week, CSF culture was 'sterile'.



THE RAJAHMUNDY DIAGNOSTIC LABORATORIES PVT.LTD
76-3-1, Gandhipuram-2, Near Prakash Nagar Round Park(Southside)

Ph : 2469438, 2467123

Patient's Name: A.SWATHI NAGAMANI.

Age:10 Y Sex:FEMALE

Ref. by Dr.K.ANURADHA. DHMS.

Dt: 24-06-1997

CULTURE REPORT

Ref.No : 563/17

Date : 24-06-1997


Nature of Material : "CSF"

Investigation :C/S

Date of Receipt : 23-06-9917

Date of Report :24-06-1997

Culture Report : No growth obtained in culture.


Signature
Dt: 24-06-1997

Suggested clinical correlation. Discuss if there is discrepancy

Second prescription

Calcareo phosphorica, 30c was selected as remedy of choice to stimulate bone growth at the defect site.

- ⦿ The child did not improve even after increasing the potency to 200c.
- ⦿ After researching through various Materia Medicas, ***Hedera helix*** was selected.
- ⦿ It was given in a potency of 30c along with Calc.phos 200c 1 dose a week.

- Dr. M.L.Tyler in her drug picture of ***Lac Caninum*** very aptly underlined the significance of perceiving the enormous therapeutic efficacy of lesser known remedies of our Materia Medica.
- As epic Greek poet Homer encapsulated in his famous saying in the *Odyssey* “often a small rock holds back a great wave.”

Very often small rock holds back a great wave.



- ◎ The so called smaller remedies are in fact not any way smaller in the linguistic expression of the word but are mere less often brought in to play and most importantly when they are indicated they do just as good work as any poly crest remedy can achieve.

- The condition of the patient was improving slowly, the continuous flow gradually decreased to drops.
- At this stage the child happened to be drenched in a heavy rain and caught cold and cough.
- *Arsenicum album*, 30c was prescribed.
- Pt was relieved of cold and cough.

- Aggravation and recurrence of the CSF rhinorrhoea due to disturbance of newly forming bone(calus) of cribriform plate.
- Potency of *Hedera helix* was increased to 200c one dose a day and *Calc.Phos.* to 1M one dose a month.

- ⦿ Patient was completely asymptomatic in 2 months.
- ⦿ Stopped taking the drug for convulsions.







THANK
YOU...