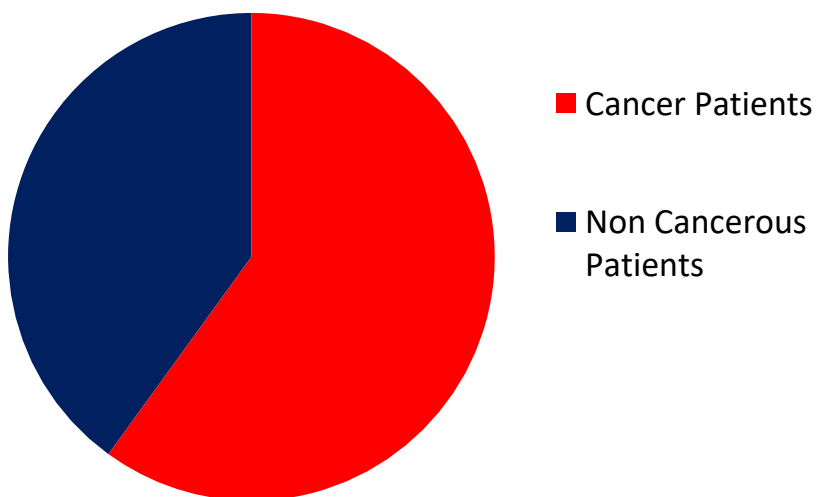


Efficacy of Constitutional Homoeopathic Drugs In The Management Of Advanced Cancer – A Prospective Study

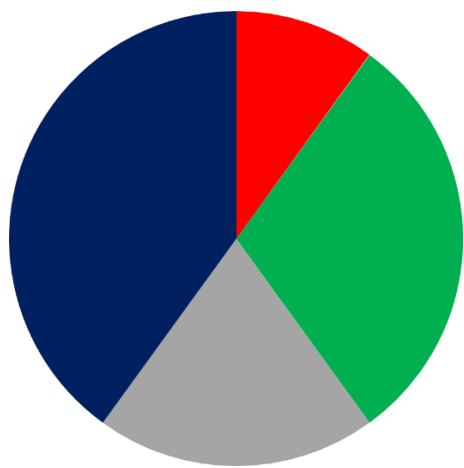
Author – Dr. Farokh Master, Dr. Rukshin Master

Our practice consists of 60% cancer patients and 40% of non-cancerous patients

OUR PATIENT DATABASE



HOW DO WE CATAGERIZE HOMOEOPATHIC TREATMENT



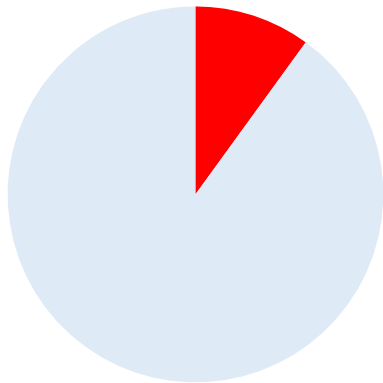
■ No Surgery, No Chemo, No Radiation, Only Homoeopathic Treatment 10%

■ Surgery done, No Chemo, No Radiation, Homoeopathic Treatment 30%

■ Sugery done, Chemo done, No Radiation, Homoeopathic Treatment 20%

■ Surgery done, Chemo done, Radiation done, Homoeopathic Treatment 40%

Homoeopathic management



Here the focus is on giving Constitutional Homoeopathic Treatment.

One needs to give frequently intercurrent Anti-Sycotic Remedy to reduce the size of the tumour.

If the patient develops an acute complaint, then we give an acute remedy based on his acute totality.

P.S. – There is no necessity for an Organ Remedy.

IMPORTANT ANTI-SYCOTIC REMEDIES USED

• Anacardium

• Arsenic Iodide • Asteria Rubens • Aurum-iodide

- Aurum-metallum • Baryta-iodide
- Bromium
- Calcarea-flour • Carbo Animalis
- Cistus canadensis • Condurango
- Conium
- Flouric acid • Hydrastis
- Iodium
- Phytolacca • Plumbum
- Plumbum Iodide • Ruta
- Scirrhinum • Secale Cor • Thuja

Aim of Investigation

The aim of this prospective study was to uncover the efficacy of Homoeopathic drugs in controlling the pain and overall quality of life of cancer patients who were already on heavy doses of opiates and non opiate painkillers.

Research Methodology

- Study conducted at Homoeopathic Health Center, K.E.M. Hospital (Mumbai) and Ruby Hall Hospital (Pune)
- Research design – Prospective Case Series Method • Sample Size – 30

Inclusive criteria

- Patients having Cancer
- Patient who are taking opiates and non opiate painkillers for at least 7 days

Methods

- We selected 30 patients who regularly attended our cancer clinic for a minimum period of 9 months.
- Evaluation was based on their type of pain, e.g. burning, stabbing, spasmodic, etc.
- The duration of the pain was noted along with its pathophysiology, e.g. somatic, visceral, neuropathic, etc. Most importantly the pain score from 0 to 10 was used to label the intensity of pain. Furthermore every patient was evaluated using Karnofsky Performance Scale, European Organization for Research and Treatment of Cancer QLC -C30 (Version 3) and The Short Form (36) Health Survey.
- Before starting Homoeopathy the total use of opiates and non opiate painkillers tablets was evaluated and their respective dosage was noted.

- In the first two weeks the dosage was unchanged but subsequently the dosage was reduced to see the effect of Homoeopathic medicine on the cancer pain.
- Detailed homoeopathic evaluation of the patient was done, determining his past and family history, his physical constitution, his physical general symptoms, his mental symptoms and his life space.
- Single homoeopathic drugs were selected in different potencies and administered by a special 5 cup method dose and patients were observed over a minimum period of 9 months. Evaluation after the remedy was done using Karnofsky Performance Scale, European Organization for Research and Treatment of Cancer QLC -C30 (Version 3) and the Short Form (36) Health Survey

Results

- The results were very encouraging.
- More than 70% of the patients irrespective of the type of cancer and type of pain felt improvement in their pain.
- More than 60% of the patients reduced their opiates and non opiate painkillers by more than 60%.
- They felt their energy levels and feeling of well being improved by almost 80%.

Conclusions

- From this study we could positively conclude that Homoeopathic medicines were able to provide the cancer patients with a significant relief in their pain without causing any adverse effects.
- In fact they were able to improve the overall condition of the patient and give them a sense of well being along with an improvement in their energy levels

A Case of Carcinoma of Prostate Gland With Bony Metastasis in Pelvic Bone, Femoral Head, Neck and Diaphragm

62 years old male came to us on 4 November 2009 with the complaints of:

§ Burning pain in urethra before, during and after micturition since 3 months.

§ Pain in the pelvis and bilateral hip which is worse after exertion; motion and walking.

§ Unable to lie down on painful side.

§ Chronic constipation.

§ Tendency to catch cold.

§ Nausea from strong odors.

§ Appetite poor, with weight loss (8 Kgs in last 4 months).

Enlarged Prostate - Size 3.7 x 3.7 x 3.6 cm

Weight 26 gms

9th October, 2009

PSA - 98 ng/ml (Normal range = Up to 4)

12th of October, 2009

Prostatic adenocarcinoma of Gleason's Score 4 + 3 = 7

MRI Scan of Pelvis 22nd of October, 2009

- Replacement of T2 hyperintensity of the peripheral zone of prostate by hypointense suggestive of neoplasm.
- Involvement of seminal vesicles and urinary bladder neck.
- Metastases in pelvic bones and upper femoral head, neck and diaphysis.

Past Illnesses:

- Known case of ischemic heart disease post CABG – 1999
- Lithotripsy of renal calculi - 2005

Habits

- Smoking 8 to 10 cigarettes in a day since 1965.
- Alcohol twice a week.

Family History

Father- Died – 84 Chronic bronchitis

Mother Died – 85 - Cancer of breast with metastases

Generals

Eats food hurriedly

Thirsty with frequent intervals

Chronic constipation, dependent on laxatives

Perspiration

- Forehead, < while eating spicy or pungent food.
- Axilla.

Desires and Aversion

Desires - Fried food, Pungent, Spicy,

Aversion - Fruits

Sleep - Sleeps on the right side, slightest noise aggravates.

Snoring during sleep. Has to cover his legs during sleep.

Mind

Hot tempered.

Dominating.

Gets angry on contradiction.

Loves travelling and adventure.

Loves nature and animals.

Has been very successful throughout his life except in 1995, when he had a major financial loss - This loss affected his life style and also brought him a lot of embarrassment and sadness.

Prefers solitude.

Hides his emotions – Reserved

He is extremely careful about his image and position in society and hence the financial loss was a major set back to him.

He felt the financial loss humiliating, as when he had money he helped his friends and relatives but when he was in need his friends and relatives deserted him.

His only daughter was another disappointment in his life who married against his wish to a person he strongly disapproves – this affects him severely.

In August 2009 when he was diagnosed with cancer of prostate none of his relatives phoned him or asked for him, also his only daughter never enquired about his health. He felt this humiliating and as a result depression set in.

Does not talk much with people around.

Cannot take failures easily.

Treatment Given

Lycopodium clavatum 30C

Follow upon 10 January, 2010:

Pain in the pelvis and hips improved. • Constipation better.

Nausea better.

Appetite improved. • Energy levels better.

Treatment Given

Lycopodium Clavatum 30C

Follow up on 22nd April, 2010:

Burning pain during urination better.

Hips and pelvis pain getting better.

Constipation better.

Nausea better.

Appetite better.

Energy levels better.

Has gained weight by 2 Kgs (initially it was 66 Kgs and now it is 68 Kgs).

His liver function test, which was abnormal, is getting normal.

PSA 0.9 ng/ml (Normal range = Up to 4)

Treatment Given

Lycopodium clavatum 30C

Follow up on 28th June, 2010

Hip and pelvis pain getting better.

Appetite better.

Energy levels better.

PSA 0.9 ng/ml (Normal range = Up to 4)

Liver function test totally normal.

His present weight is 70 Kgs.

Treatment Given

Lycopodium clavatum 30C

Follow up on 7th January 2011

Huge emotional stress, partly domestic and partly business.

He has lot of arguments which is family members regarding selling of real estate.

This makes him cry very bitterly.

Treatment Given

Lycopodium clavatum 30C

Follow up on 24th April, 2011

The patient did not come for regular follow ups as he was busy in legal works, also he went in to depression with lot of suppressed anger.

Started developing suicidal thoughts.

Locks himself for hours together in a room or else goes out of the house and roam around on the street aimlessly.

He decides not to take any medicine and wants to die because his ego was hurt that people around him were not treating him the way he should be treated.

Physically there were no symptoms.

He lost 2 Kgs of weight because he was not eating properly.

He was forcefully brought to my clinic by his son and wife.

His smoking habit is also increased tremendously.

Treatment Given

Lycopodium Clavatum 30C

Follow up on 27th December, 2011

Severe pain in the left arm, < Exertion and Motion

No self confidence.

Weeps when things are not done his way.

Frequently says 'I am of no use to the family'.

Feels he is a failure and helpless.

Suicidal thoughts.

He feels weak in the evening.

Desire for fat, spicy and pungent food.

Aversion to fruits.

Since there was no major improvement seen in the patient the case was reanalysed.

Treatment Given

Aurum muriaticum natronatum 30C

Follow up on 4th January, 2012

Pain in the arm much better.

Suicidal thoughts - better.

Confidence better than before.

Weakness better.

Over all he is better.

Treatment Given

Aurum muriaticum natronatum 30C

Before Treatment

Pain score: 5

Karnofsky performance status scale: 60

European organization for research and treatment of cancer QLC-C30 (Version 3):

Overall health before starting the treatment at scale 5

Overall quality of life before starting the treatment at scale 5

After Treatment Given

Pain score: 2

Karnofsky performance status scale: 90

European organization for research and treatment of cancer QLC-C30 (Version 3):

Overall health after starting the treatment at scale 6

Overall quality of life after starting the treatment at scale 6

RECURRENT SQUAMOUS CELL CARCINOMA OF ORAL CAVITY

Squamous cell carcinoma of oral cavity Left side

Left hemimandibulectomy and left Supra Omohyoid Neck Dissection (SOHD) done

Cancer left lower alveolus grade II and Cancer buccal mucosa

On Radiation Therapy

Reduction in size of oral commissure

Micro commissure (Post Radiation Therapy)

Vestibuloplasty (A surgical procedure to restore alveolar ridge height by lowering muscles attaching to the buccal, labial, and lingual aspects of the jaws)

Oral cavity cancer (October 1999)

SOHD (December 1999)

Cancer alveolus and cancer buccal mucosa (April 2000)

Patient was apparently all right from year 2003 to 2010

In January 2011 he presents with recurrence of cancer of buccal mucosa and alveoli

He was advised Anti-epithelial Growth Factor Chemotherapy with Radiation Therapy

Cancerous growth - 29 March 2011

Post radiation complication in oral cavity

1. Microcommissure

2. Pain oral cavity due to generalized inflammation from previous Chemotherapy and previous radiotherapy

< Talking < Eating

< Drinking < Touching

3. Painful ulcers (on the tumor mass) in the oral cavity < Touch

< Eating

< Drinking

4. Pricking pain in the cancerous site

5. Loss of 6 kilograms weight in 1 month

6. Absolute lack of appetite

- 7. Excessive salivation – Sticky, dribbling; Has to be cleaned every few minutes
- 8. Weakness on slightest exertion; Cannot sit or stand for long time; has to lie down

Pain score: 7

Karnofsky performance status scale: Rating %: 50

European organization for research and treatment of cancer QLQ -C30 (version 3):

Overall health before starting the treatment at scale 3 Overall quality of life before starting the treatment at scale 3

Past illnesses:

Bilateral inguinal hernia Operated

Family History:

Father Died 40

Mother Died 50 Fever

Brother 1 Died 75 Typhoid

Brother 2 Alive Diabetes Mellitus

Habits:

Tobacco chewing for 33 years.

Whiskey (10 ml.) 4 times a week for 35 years.

Tea 6 cups in a day daily

Urination:

7-8 times during daytime 2 times in the night

Stools:

Once a day, normal

Perspiration: Forehead

Sleep: Sleeps on back

Grinding teeth during sleep Dribbling saliva during sleep

Craving for sweets

Milk Aggravates

Aversion Meat

Mentals:

Anxious and nervous before visiting doctors.

Disciplined. Fastidious. Gets hurt easily.

Hard working- Too much sense of Duty. ☑Helping others without making big show. ☑Punctual.

Wants company (but at present does not want to meet anybody because of his deformity of the mouth and salivation). Fears his condition is being observed.

Does not want to become a burden to his children or his relatives; feels bad that his sons are spending money, time and energy behind him

Recently due to illness, especially because of pain and salivation, he has become quite irritable.

Reserved. Strong will power. Very sensitive.

Would never show his pains and hurts to others, keeps it to himself.

Keeps quiet when someone does not listen to him – avoids confrontations.

Does not like wife and his children spending excessive money on luxury.

Always follows his routine life:

Watching news-health related

Reading newspaper- health columns

Greatest Grief:

Death of mother; he was emotionally very attached to his mother.

Life History: Born in Pakistan. Studied in Dehradun.

After his sister got married he started working with his brother-in-law in truck business.

Later he was in this business till cancer developed. His children are well qualified and well settled in life.

Treatment:

Calcarea carbonica 30C

The following complaints were better more than 80% :

Pain in the ulcer ☑Size of the tumor

Pain in the right side of the face ☑Salivation

Sleep

Hoarseness of voice

On 11 May 2011, suddenly all the complaints especially pain increased tremendously.

With this pain there was ☑Excessive salivation ☑Excessive thirst and

Severe inflammation around the gums.

Medicine changed to Mercurius solubilis 30C, five cup method, 1 tsp every 4 hourly.

Mercurius solubilis 30C was continued till 29 June 2011.

The following improvement was noticed: ☑The pain disappeared

The salivation reduced

On 15 August 2011, the improvement was persisting but the only problem was the size of the tumor and the weight gain was absent.

Prescription:

Thuja occidentalis 30C,

Improvement:

Tumor regressed more than 90%

Pain score: 3

Karnofsky performance status scale: Rating %: 70

European organization for research and treatment of cancer QLQ-C30 (version 3):

Overall health after the treatment at scale 6 Overall quality of life after the treatment at scale 6

Case of a moderately differentiated Squamous cell carcinoma of Left Buccal Mucosa

62 yrs old pt consulted us in September 2015 for CA oral cavity.

2000: had lesion in left buccal mucosa. Investigation were negative for Ca.

Rx: taken for lesion.

2013: lesion on Lt side of buccal mucosa. (benign)

Investigation were negative for Ca. and got operated for the lesion.

April 2015: Recurrence of lesion on same side of buccal mucosa.

Investigation: Biopsy done which showed moderately differentiated Squamous Cell Carcinoma of left Buccal mucosa.

Got operated (wide excision of left cheek local skin flap under GA). Tumor infiltrates to maximum depth of 0.5cms.

July 2015:

Pt took 30 sittings of radiation and 60 days of Chemotherapy

Started with :

- Swelling on left side of face. Unable to open mouth.
- Trismus
- Weight loss 10kgs

FAMILY HISTORY

Father - Dead - 72yrs - IHD

Mother - Dead - 83yrs - Fracture

Sister – Dead - 69yrs - Cellulitis

Brother - Alive - 64yrs - CABG, DM, Gall-stone

Brother - Alive - 57yrs - DM

Appetite And Thirst

Appetite : Average. Can eat only soft diet or liquids.

Desire : spicy food ++ Thirst: average

Bowel, Bladder and Perspiration

Stools: normal Urine: normal

Perspiration: forehead and scalp.

Thermals and Sleep:

Ambithermal Chilly Cannot tolerate cold now.

Sleep : on right side

MIND

Confident

Weeps easily on seeing sufferings of others.

Desires company.

Anger easily on contradiction.

Strong will power.

Fearless

Injustice cannot support. Cannot tolerate anything wrong.

Short- temper

Childhood was very good.

He was the chairperson of his society.

I have been satisfied with people and life.

In 1992, few men demanded money from him. Was about to kidnap him. Was shot on hand.

Was a gold smuggler. Then quit and started a jewellery store.

Has worked hard in his life.

Says he has lot of contacts. Never got into any addiction. Never quit my religion.

Cannot sit idle. Wants to do some activity all the time. Use to do lot of social work as well.

In 1973, 1980 – has even been put behind the bars.

Inspite of all this, he has helped lot of people.

He is a family man.

Used to tell his wife. Don't ever ask him if he is going to be back home. (as he was into risky business).

I taught my children that only if family is together , “you’ll be successful”

The patient feels that he is very blunt. Talks / answer back on people’s face. Never kept things within.

5yrs back – lost a lot of money in gambling (MCX)

Had to sell off his property to clear the debts.

Then his brother helped him and his children to get settled.

Treatment Given

Phytolacca 30

Follow- up 24th Sep 2015

Face swelling > Salivation --- SQ Thick saliva at night

Mouth dryness after eating.

Treatment Given

Phytolacca 30

Follow – up 12th Oct 2015

Dryness of mouth

Thinks there is no saliva in mouth

Pustular discharge around the eye >> but still present No pain or burning

Itching left eye

Treatment Given

Phytolacca 200 C

Follow – up 26th Oct 2015

Pain in left eye < Anger due to pain

Pustular discharge on lateral side of left eye.

Treatment Given

Phytolacca 200 C

Follow – up on 27th Oct 2015

Pt. was much better in pain>>

Pus discharge from eyes >

Treatment Given

Phytolacca 1 M

Follow – up on 2nd Nov 2015

- Pain around left eye better than before.
- Pustular boils inside oral cavity and around mouth.
- Offensive odor from the left eye
- Pustular discharge increases after application of ice.

Treatment Given

Phytolacca 1 M

Follow – up on 5th Nov 2015

- Stiffness on left side of face extending to neck • Numbness of left side of face
- Pustular discharge from mouth • Halitosis
- Unable to open mouth. • Pain around eyes >

Treatment Given

Phytolacca 10 M

Follow – up 16th Nov 2015

- Feeling much better
- Dryness of lesion
- Discharge >>
- Offensive odor >>

Treatment Given

Phytolacca 10 M

Follow Up - 3rd December 2015

- Pain much better only 10-20 percent remaining.
- Appetite much better
- Trismus
- Difficulty in walking on account of weakness.

Treatment

Phytolacca 10M

SQUAMOUS CELL CARCINOMA OF TONGUE

Partial Glossectomy (1994)

Recurrence (1995)

Partial Mandilectomy (1996)

Male 46 years old came to us in September 1996

Complains of:

Red small ulcer on the tongue (Recurrence of cancer)

Sometimes slight burning sensation but no pain

Wants to prevent future recurrence Acidity - H/O small ulcer in the stomach

(Used to antacids in

take Allopathic medicine like the past for acidity)

Perspiration:

Do not perspire much

Food and Drinks: Desires

Sweets

Milk products

Fish

Eggs

Life History:

Born in Mumbai

His elder sister died when she was few months old so he is the eldest son in his family

POVERTY:

He had to face financially difficult time in childhood

He failed in his inter-science and had to take up a job to support the family financially

After he got the job in a bank he again started studying and completed his B.A.

Father died of brain hemorrhage in 1971 and at that time he was the only earning member in his family

He had to look after for his mother and 3 younger brothers, they were studying in school at that time, so it was a great responsibility for him

Love marriage

1983: Sudden shock

Lost his son, he got drowned in a drum of water

Mentals:

Gets tensed very fast (in office as well as at home)

Now he tries to avoid getting tensed

Any quarrel makes him disturb very fast, he wants peace

Fear of getting cancer

Many years back his grand father got cancer and few years back he saw one of his aunt died of cancer

Not punctual in the office but he is good at his work

Religious

Hobbies: Listening to music and watching TV especially sports

Likes company but at the same time he does not like crowd also

Sleeps late at around 1 a.m. after finishing his prayers

Over protective about his younger brothers after his father

Family oriented

TREATMENT

September 1996

Carcinosinum 30C

Follow up October 1996:

- Red small ulcer on the tongue gone • No recurrence or nodule
- No burning sensation

Treatment:

Carcinosinum 30C was continued till September 1997

Follow up in September 1997

- No recurrence or nodule • Energy level good
- General health good • No complaints
- No allopathic drugs taken during this period

TREATMENT:

Carcinosinum 1M, one dose every month for one year From 1997 to 2004 he was kept under observation.

There was infrequent repetition of the medicine till the next follow up.

Follow up in August 2004

No recurrence at the primary site nor at the secondary site

Weight 42 Kgs

Energy level good

General health good

No complaints

TREATMENT

Carcinosinum 1M, 1 dose every month for 3 months.

From November 2004 to February 2008 he was on placebo.

Follow up in February 2009

No recurrence at the primary site nor at the secondary site

Weight consistently the same - 42 Kgs

Energy level good

General health good

No complaints

TREATMENT

Placebo till the next follow up. It was continued till 2010.

Follow up September 2014

Patient has been coming for a routine check-up on and off.

He has been doing well.

There has been no recurrence of his disease.

He is living a healthy life.